

# Axenfeld Nerve Loop

**These are rare congenital anomaly that can be confused with naevi or even melanomas or cysts.**

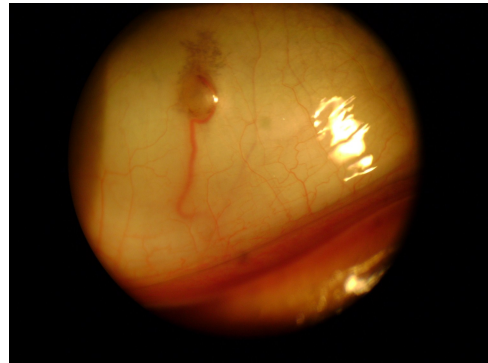
The long posterior ciliary nerve is not normal seen as it is inside the outer coat of the eye. However rarely it can make a loop through the sclera (outer coat of the eye) close to the anterior ciliary arteries. The loop appears as a smooth dome shaped elevation about 2mm in diameter. The loop may appear cystic or pigmented but is in fact not. They are rarely bilateral (1% of cases) and rarely there are more than one in one eye (0.5%).

As they are nerves pain can be elicited if they are touched or pressed.

## **Treatment.**

None – specifically as they are not cysts etc they should not be operated on.

They are harmless and need no treatment.



It is named after Theodor Axenfeld who was a German Ophthalmologist (1867 to 1930). He was involved in many areas of Ophthalmology and wrote over 200 works. He was the first to describe this.

**Mr. Lee 2011**